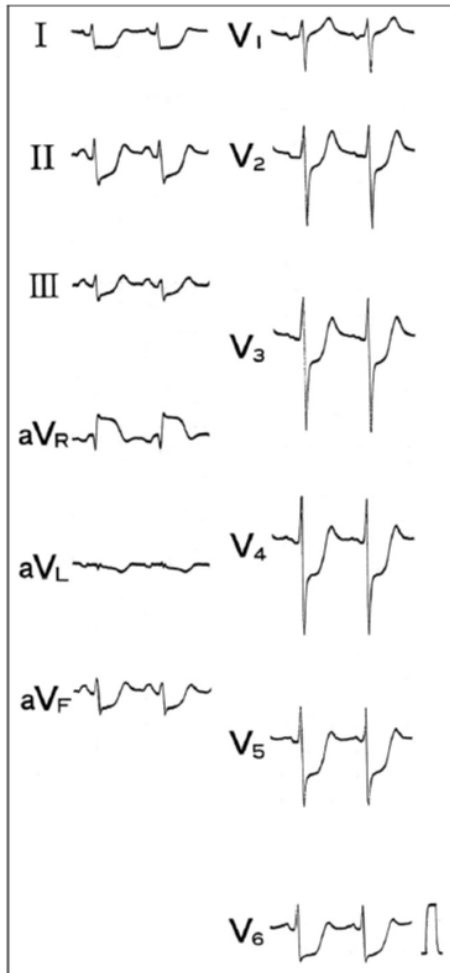


4 STEMI Equivalents (Any ECG finding a/w coronary occlusion but lacking classic ST-elevation)

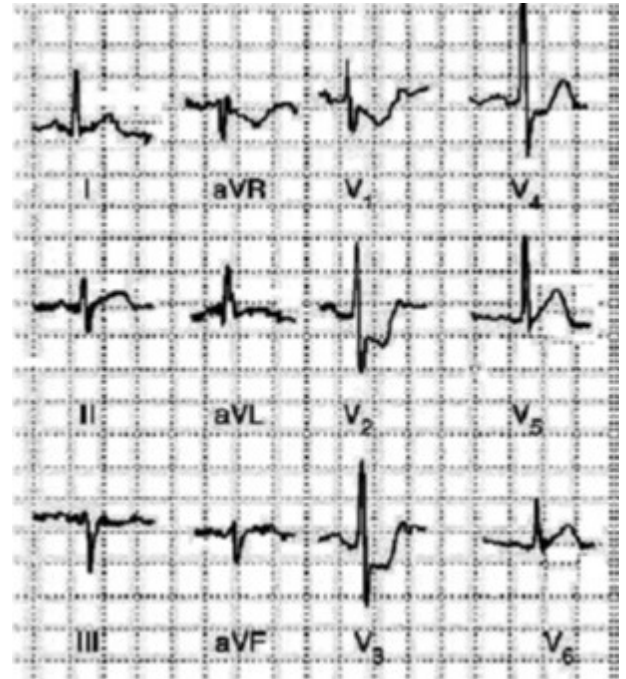
The Widow Maker

Multilead ST depression + ST elevation in aVR (both >1mm) suggests left main or proximal LAD occlusion



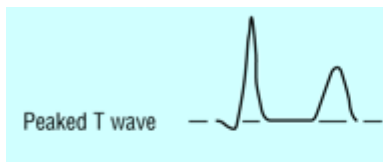
Posterior MI

ST depression in ≥ 2 precordial leads (V1-V4) +/- Tall R wave & prominent, upright T wave



Hyperacute T-waves

Tall, symmetric T-waves -> Obtain serial EKGs, look for STEMI

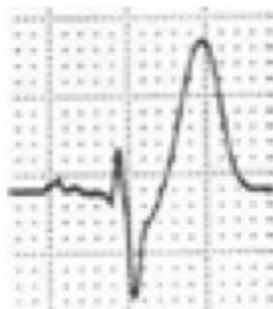

DeWinter/ST-TW complex

ST depression ≥ 1 mm up-sloping at the J-point in leads V1-V6

WITH

Tall, upright, & symmetric TW



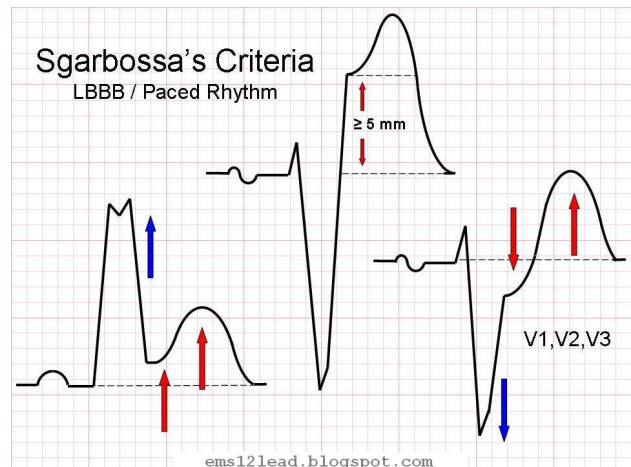
Sgarbossa Criteria

Emergent reperfusion in LBBB and suspected ACS if:

1. ST elevation ≥ 1 mm and concordant with QRS complex
2. ST depression ≥ 1 mm in lead(s) V1-V3
3. HD instability or acute heart failure

Sgarbossa's Criteria

LBBB / Paced Rhythm



V2.2 by Christopher Barsi / Oct 22, 2015 / References

1. Am J Cardiol 2011;107:495-500
2. BMJ 2002;324:831-834
3. Emerg Med J 2012;29:15-18
4. ems12lead.com/2014/06/04/just-a-paced-rhythm-or-it/
5. Heart 2009;95:1701-1706